

# Assessment of SIAscopy in the triage of suspicious skin tumours

D. Sgouros<sup>1</sup>, A. Lallas<sup>2</sup>, Y. Julian<sup>3</sup>, D. Rigopoulos<sup>1</sup>, I. Zalaudek<sup>2,4</sup>, C. Longo<sup>2</sup>, E. Moscarella<sup>2</sup>, V. Simonetti<sup>2</sup> and G. Argenziano<sup>2</sup>

<sup>1</sup>Second Department of Dermatology, Athens University School of Medicine, Attikon General University Hospital, Chaidari, Athens, Greece,

<sup>2</sup>Skin Cancer Unit, Arcispedale Santa Maria Nuova IRCCS, Reggio Emilia, Italy,

<sup>3</sup>Dermatology Unit, Hospital General de Agudos "Dr. Cosme Argerich", Buenos Aires, Argentina and <sup>4</sup>Department of Dermatology, Medical University of Graz, Graz, Austria

**Background/purpose:** Spectrophotometric Intracutaneous Analysis (SIAscopy) is a non-invasive, computerized technique for the diagnosis of pigmented skin tumours. The analysis is based on the evaluation of skin chromophores, i.e. melanin, haemoglobin and collagen within the epidermis and papillary dermis. Our aim was to assess the diagnostic validity of SIAscopy in the detection of melanoma and non-melanoma skin cancers compared to the clinical-dermoscopic diagnosis and the histopathologic results of the excised lesions.

**Methods:** In total, 188 lesions of 180 patients were examined by dermoscopy and SIAscopy. A SIAscopy scoring system was first compared with the clinical-dermoscopic diagnosis and then with the histopathologic diagnosis of the excised lesions.

**Results:** With respect to the clinical-dermoscopic evaluation, SIAscopy had sensitivity and specificity values of 85.7% and 65.4% respectively. Of the 188 evaluated lesions, 44 were excised with histopathologic examination revealing 31 malig-

nant tumours, including 18 melanomas. With respect to histopathology SIAscopy had a sensitivity of 83.9%. Seven of the 13 benign excised lesions were scored as malignant by SIAscopy resulting in a specificity of 46.1%.

**Conclusion:** SIAscopy cannot replace the standard of care in skin cancer diagnosis, which includes clinical and dermoscopic examination. However, considering that the technique does not require specific training and expertise, it might represent an additional, relatively cost-effective tool to select lesions for referral.

**Key words:** siascopy – spectrophotometric intracutaneous analysis – dermoscopy – melanoma – skin tumours

© 2014 John Wiley & Sons A/S. Published by John Wiley & Sons Ltd

Accepted for publication 5 January 2014

EARLY DETECTION of melanoma represents the only strategy to reduce the disease-related morbidity and mortality. However, melanoma recognition is complicated by the exceedingly high incidence of benign pigmented skin tumours from which melanoma has to be differentiated (1). Thus, a tremendous number of pigmented lesions have to be examined to detect the suspicious ones (2). This challenge involves not only the specifically trained dermatologist, but also less experienced clinicians, including primary care physicians (3), with clinical diagnostic accuracy values ranging from less than 50% for inexperienced physicians to 80% for expert dermatologists (4–6).

Undoubtedly, the introduction of dermoscopy initiated a new era in melanoma screening, as the additional morphologic information provided by dermoscopic examination significantly

improves the accuracy in melanoma diagnosis (7). Even in a non-specialized clinical setting, dermoscopy has been shown to enhance the better selection of lesions to be referred to specialists (8). However, dermoscopy is associated to two main drawbacks, namely the highly subjective interpretation of criteria and the time needed for training and acquiring experience. A recent study involving primary care physicians showed that the combination of dermoscopy and digital monitoring increased the sensitivity of melanoma diagnosis, but training in these techniques required considerable time and was completed by only 62% of the clinicians (9).

Spectrophotometric Intracutaneous Analysis (SIAscopy) is a novel diagnostic method, developed in an attempt to introduce a diagnostic tool overcoming the two problems mentioned above (10). Instead of focusing on image pattern

analysis, SIAscopy uses light reflected from the skin in the visible and infrared spectra to produce images of the epidermal and dermal melanin, the vasculature and the dermal collagen content within the lesion. The interpretation of image colours allows estimations of the underlying histopathologic features. Specifically, a hand-held scanner (SIAscanner) probes the skin and scans it with light (contact type). There is also the non-contact type where a digital camera with a special filter is used to produce images of larger areas of the skin. The device emits harmless radiation, ranging from 400 to 1,000 nm into an area of  $24 \times 24$  mm or  $12 \times 12$  mm and then measures the reflected light quantity for each wavelength (11, 12). The skin and its components absorb and/or reflect light to various degrees and can interact preferentially with specific lightwaves. The SIAscope extracts information regarding the location, quantity and distribution of the skin chromophores, including melanin, collagen and haemoglobin within the epidermis and papillary dermis, producing eight narrow-band spectrally filtered images and then displays a characteristic SIAscopic image. Data are then displayed via SIAgraphs, which are graphical representations of the digital information (13).

In the current manuscript, we present our experience on the use of SIAscopy in the everyday clinical routine of a busy pigmented lesion clinic. Our aim was to assess the diagnostic accuracy of SIAscopy in the diagnosis of malignant pigmented skin tumours, compared to the clinical-dermatoscopic diagnosis and the histopathologic results of the excised lesions.

## Materials and Methods

Patients were enrolled prospectively over a 3-month period at the Skin Cancer Unit of the Arcispedale Santa Maria Nuova IRCCS in Reggio Emilia, Italy. Inclusion criteria were the presence of a pigmented skin tumour, clinically suspicious for the diagnosis of melanoma, basal cell carcinoma (BCC) or squamous cell carcinoma (SCC) and the inability to establish a definite diagnosis on clinical grounds only. Each lesion was examined clinically, dermoscopically and with the contact type SIAscope. None of the lesions was managed based on the score achieved by SIAscopy, but the decision to excise, monitor or ignore an individual lesion

was based on clinico-dermoscopic assessment, as in routine daily practice.

The SIAscopic scoring system used was the primary care scoring algorithm (PCSA), as introduced by Emery et al. in 2010 (Fig. 1) (14). A lesion score was the final outcome of the SIAscopy analysis. Lesions achieving six or more points were regarded as suspicious, while those scoring less than six points were considered benign.

Sensitivity, specificity, positive and negative predictive value of SIAscopy was calculated in comparison to the clinico-dermoscopic examination, as well as to the histopathologic diagnosis of the excised lesions.

## Results

One hundred and eighty-eight lesions from 180 patients were included in the study. Of the 180 patients, 91 (50.6%) were females. Patients' age ranged from 2 to 95 years with a mean age of 43 years. Thirty five of the 188 included lesions (18.6%) were diagnosed as malignant after clinico-dermoscopic examination and subsequently excised. Among them, 21 lesions were suggestive of melanoma, 9 suggestive of BCC and 5 suggestive of SCC. Thirty of these 35 lesions (85.7%) scored six or more points by SIAscopy, thus being in the suspicious range (sensitivity comparing to dermoscopy, 85.7%). Of the 153 lesions considered benign after clinico-dermoscopic assessment, 122 were diagnosed as nevi, 23 as seborrhoeic keratoses (SK), 7 as dermatofibromas and 1 as cherry angioma. SIAscopy gave a negative score (<6) in 100 of these 153 lesions, resulting in specificity, comparing to dermoscopy, of 65.4%.

Nine additional lesions, although judged as benign in clinico-dermoscopic examination were excised following patients' demand, thus accounting for a total of 44 excised tumours. The histopathologic examination of the 44 excised lesions revealed 31 malignant (18 melanomas, 10 BCCs and 3 SCCs) and 13 benign tumours (12 nevi and 1 SKs). Comparing to histopathology, 26 of 31 malignant lesions were scored as such by SIAscopy, resulting in a sensitivity of 83.9%. Of the 13 excised benign lesions, seven lesions were scored as malignant by SIAscopy (specificity comparing to histopathology, 46.1%). All of these seven false positives had a diameter larger than 6 mm. Overall,

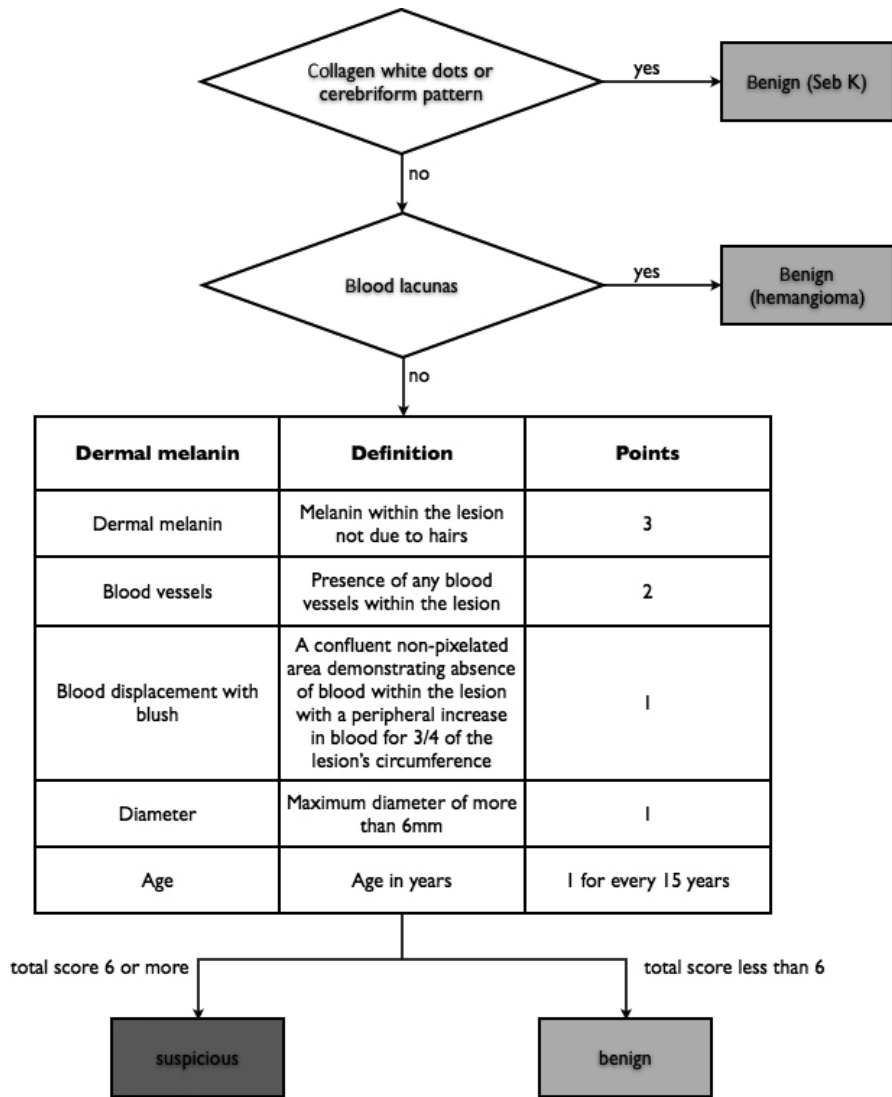


Fig. 1. The SIAscopic scoring system used in the study.

the mean SIAscopy score of malignant and benign lesions was 7.1 points and 4.9 points respectively.

## Discussion

In our study SIAscopy had lower accuracy than dermoscopy, in terms of sensitivity and specificity, for the diagnosis of a series of clinically suspicious pigmented tumours. However, the role of SIAscopy should not be viewed as a replacement of the standard diagnostic procedure to select lesions to biopsy, but as an additional tool in the hands of less experienced clinicians, including primary care physicians, to select lesions for referral. The dual advantage of SIAscopy is to minimize the subjectivity of the assessment while requiring no training and specific

experience (12–15). In the context of a primary care setting, a SIAscopy sensitivity and specificity of 85.7% and 65.4%, respectively, could be considered acceptable.

Interestingly, we noticed that 35 of the 53 benign lesions scoring six or more points had a diameter greater than 6 mm. Although the SIAscopic features were not individually evaluated, the latter observation indicates that a correction of the impact of the large diameter of a given lesion on the total SIAscopic score might improve the specificity rate of the method. Using the revised scoring system for SIAscopy, the mean score of malignant and benign lesions in our study was 7.1 points and 4.9 points respectively. Thus, the suggested threshold of six points between benign and malignant lesions seemed to work properly.

Previous studies have investigated the diagnostic accuracy of SIAscopy for melanoma diagnosis. Moncrieff et al. introduced the first scoring system in a study including a set of lesions already referred for surgical excision and reported a sensitivity of 82.7% and a specificity of 80.1% (12). However, these results cannot be applied to primary care screening, as the latter study assessed the value of the method on lesions that had already been judged to merit excision. Govindan et al., using the same scoring system, found a sensitivity of 94.4% for melanoma diagnosis, but their study also included only referral cases (16). To enhance the applicability of the method in primary care screening with the less possible decrease in specificity rates, Emery et al. introduced the PCSA, incorporating in the Moncrieff scoring system two initial steps that aimed to avoid misclassification of SKs and haemangiomas as suspicious (14). Testing the PCSA in a primary care setting, the authors found a sensitivity of 50% and a specificity of 84%, concluding that SIAscopy could play a useful role in improving primary care management of pigmented skin lesions (14). The PCSA was later integrated with a hand-held SIAscopy scanner to create the MoleMate system that we used in our study (17).

A randomized controlled trial (RCT), conducted by Walter et al. in 15 general practices in eastern England, assessed the value of the MoleMate system in improving the accurate referrals of suspicious pigmented lesions (18). To do so, the authors used a control group that applied the guidelines on referral for suspected skin cancer, which included clinical and dermoscopic examination. The investigators found that the systematic application of best practice guidelines alone was more accurate than the MoleMate system. Our findings are in line with the results of the latter RCT, supporting further that the diagnostic accuracy of SIAscopy is not comparable to clinico-dermoscopic examination. However, a secondary outcome of the study by Walter et al. was that although SIAscopy had lower accuracy than the guidelines-based ideal clinical practice, it performed better than reports of real current practice (18). The latter

observation is of particular interest, given that the ideal clinical practice by definition includes application of dermoscopy that requires a long training process, which, as previously shown, only specialized clinicians are prone to complete.

In our study, 9/10 BCCs and 2/3 SCCs were correctly categorized as suspicious by the SIAscopy score. Tehrani et al. previously evaluated the value of SIAscopy in the diagnosis of non-melanoma skin cancer (NMSC), reporting sensitivity and specificity rates of 97.5% and 86.7%, respectively, whereas Terstappen et al. did not find any advantages of SIAscopy over dermoscopy for the diagnosis of pigmented BCCs (19, 20). The utility of SIAscopy in the context of NMSC thus remains to be further elucidated.

Our study has several limitations. First, it was conducted in a specialized clinical setting, which, in addition to skin cancer screening, deals also with referral cases. Consequently, the calculated SIAscopy rates of sensitivity and specificity, compared to dermoscopy, cannot be directly applied in a primary care setting. Second, only a minority of lesions were excised, thus the sensitivity and specificity rates of SIAscopy, compared to histopathology, are even less applicable to a non-specialized setting. Finally, the tumours were included based on the clinical evaluation of expert clinicians in the field of skin cancer diagnosis, resulting in a selection bias.

In conclusion, our results further support the previously reported suggestion that SIAscopy cannot replace the standard of care in diagnosing skin cancer, which is represented by the clinical and dermoscopic examination. However, considering that the technique does not require specific training and expertise, it might represent an additional, relatively cost-effective tool to select lesions for referral.

## Acknowledgements

*Conflict of interest:* None.

*Financial disclosure:* Study supported in part by the Italian Ministry of Health RF-2010-2316524.

## References

1. Balch CM, Gershenwald JE, Soong SJ et al. Final version of 2009 AJCC melanoma staging and classification. *J Clin Oncol* 2009; 27: 6199–6206.
2. Lallas A, Zalaudek I, Apalla Z et al. Management rules to detect melanoma. *Dermatology* 2013; 226: 52–60.
3. Pockney P, Primrose J, George S et al. Recognition of skin malignancy.

- nancy by general practitioners: observational study using data from a population-based randomised controlled trial. *Br J Cancer* 2009; 100: 24–27.
4. Curley R, Cook M, Fallowfield M, Marsden R. Accuracy in clinically evaluating pigmented lesions. *Br Med J* 1989; 299: 16–18.
  5. Grin C, Kopf A, Welkovich B et al. Accuracy in the clinical diagnosis of malignant melanoma. *Arch Dermatol* 1990; 126: 763–766.
  6. Morton C, MacKie R. Clinical accuracy of the diagnosis of cutaneous malignant melanoma. *Br J Dermatol* 1998; 138: 283–287.
  7. Vestergaard ME, Macaskill P, Holt PE, Menzies SW. Dermoscopy compared with naked eye examination for the diagnosis of primary melanoma: a meta-analysis of studies performed in a clinical setting. *Br J Dermatol* 2008; 159: 669–676.
  8. Argenziano G, Puig S, Zalaudek I et al. Dermoscopy improves accuracy of primary care physicians to triage lesions suggestive of skin cancer. *J Clin Oncol* 2006; 24: 1877–1882.
  9. Menzies SW, Emery J, Staples M et al. Impact of dermoscopy and short-term sequential digital dermoscopy imaging for the management of pigmented lesions in primary care: a sequential intervention trial. *Br J Dermatol* 2009; 161: 1270–1277.
  10. Patel JK, Konda S, Perez OA et al. Newer technologies/techniques and tools in the diagnosis of melanoma. *Eur J Dermatol* 2008; 18: 617–631.
  11. Claridge E, Cotton S, Hall P, Moncrieff M. From colour to tissue histology: physics based interpretation of images of pigmented skin lesions. *Med Image Anal* 2003; 7: 489–502.
  12. Moncrieff MM, Cotton S, Claridge E, Hall P. Spectrophotometric intracutaneous analysis: a new technique for imaging pigmented skin lesions. *Br J Dermatol* 2002; 146: 448–457.
  13. Michalska M, Chodorowska G, Krasowska D. SIAscopy – a new non-invasive technique of melanoma diagnosis. *Ann Univ Mariae Curie Sklodowska* 2004; 59: 421–431.
  14. Emery JD, Hunter J, Hall PN et al. Accuracy of SIAscopy for pigmented skin lesions encountered in primary care: development and validation of a new diagnostic algorithm. *BMC Dermatol* 2010; 10: 9.
  15. Watson T, Walter FM, Wood A et al. Learning a novel technique to identify possible melanomas: are Australian general practitioners better than their U.K. colleagues? *Asia Pac. Fam Med* 2009; 8: 3.
  16. Govindan K, Smith J, Knowles L et al. Assessment of nurse-led screening of pigmented lesions using SIAscope. *J Plast Reconstr Aesthet Surg* 2007; 60: 639–645.
  17. Walter FM, Morris HC, Humphrys E et al. Protocol for the MoleMate UK Trial: a randomised controlled trial of the MoleMate system in the management of pigmented skin lesions in primary care [ISRCTN 79932379]. *BMC Fam Pract* 2010; 11: 36.
  18. Walter FM, Morris HC, Humphrys E et al. Effect of adding a diagnostic aid to best practice to manage suspicious pigmented lesions in primary care: randomised controlled trial. *BMJ* 2012; 345: e4110.
  19. Tehrani H, Walls J, Price G et al. A prospective comparison of spectrophotometric intracutaneous analysis to clinical judgment in the diagnosis of nonmelanoma skin cancer. *Ann Plast Surg* 2007; 58: 209–211.
  20. Terstappen K, Larkö O, Wennberg AM. Pigmented basal cell carcinoma-comparing the diagnostic methods of SIAscopy and dermoscopy. *Acta Derm Venereol* 2007; 87: 238–242.

Address:  
 Aimilios Lallas  
 Skin Cancer Unit, Arcispedale Santa  
 Maria Nuova IRCCS  
 Viale Risorgimento 80, 42123, Reggio  
 Emilia  
 Italy  
 Tel: +39 335 415 093  
 Fax: +39 069 762 5822  
 e-mail: emlallas@gmail.com